

## Removal of foreign bodies from maxillary sinus: A report of three cases

Removal of displaced foreign bodies

Onur Şahin<sup>1</sup>, Onur Odabaşı<sup>2</sup>, Toghruş Aliyev<sup>1</sup>, Birkan Tatar<sup>1</sup>

<sup>1</sup>Department of Oral and Maxillofacial Surgery, Faculty of Dentistry, İzmir Katip Çelebi University, İzmir,

<sup>2</sup>Department of Oral and Maxillofacial Surgery, Ministry of Health, Mamak Mouth and Dental Centre, Ankara, Turkey

### Abstract

The maxillary sinus is the largest paranasal sinuses and displacement of foreign bodies into it is rarely reported in literature. It is necessary to know how to treat this kind of situation. The treatment for this complication is the surgical removal of the foreign bodies. We report three cases of foreign bodies (implant, impacted third molar and root) displaced into the maxillary sinus. The foreign bodies were removed soon after their migration, using the Caldwell-Luc approach, through lateral wall of the maxillary sinus. The operations were performed under local anesthesia and postoperative recoveries were uneventful, without any signs of postoperative sinusitis for both of the patients. In conclusion, Caldwell-Luc technique is a simple approach for the removal of foreign bodies into the maxillary sinus. The great advantage of this technique is that it is performed under local anesthesia and provides direct visualization.

### Keywords

Maxillary Sinus; Migration; Caldwell-Luc; Dental Implant; Impacted Third Molar

DOI:10.4328/ACAM.5992 Received: 03.08.2018 Accepted: 04.09.2018 Published Online: 05.09.2018 Printed: 01.07.2019 Ann Clin Anal Med 2019;10(4): 513-6  
Corresponding Author: Onur Şahin, Department of Oral and Maxillofacial Surgery, İzmir Katip Çelebi University, Faculty of Dentistry, İzmir, Turkey  
GSM: +905054410192 F.: +90 2323252535 E-Mail: onursahin43@hotmail.com  
ORCID ID: <https://orcid.org/0000-0001-7816-1443>

## Introduction

Largest of paranasal sinuses, maxillary sinuses are the pyramidal shaped cavities localized within the maxillary bone bilaterally. This pyramidal base, an apex of which pointing toward the zygomatic process forms by the lateral wall of the nasal cavity. The upper wall is bounded by the base of the orbit, and the lower wall is bounded by maxilla's processus alveolaris [1]. The lowest part of the lower wall is 3-5 mm below the nasal cavity and close to the first molar and the second premolar. Maxillary sinus volume has a natural tendency to increase among life, and especially when premolars and molar teeth are extracted, maxillary sinus may expand downward [1]. Factors that play role in the process of pneumatization of the maxillary sinus are absence of tooth roots after tooth extraction and atrophic resorption of maxillary alveolar crest [2]. Resorption of the bones can occur in the toothless alveolar crest with wide maxillary sinuses. In such cases, dental implant application is needed together with the sinus lift procedure [2].

Migration of foreign bodies to paranasal sinuses is a rare but significant condition. Among the reasons for this condition are: clinicians or surgeons with less experience in surgery, perforations during sinus wall lift procedures, implants placed without sinus floor elevation in the excessively pneumatized maxillary sinus, false graft technique, poor anatomical knowledge and maxillary teeth closely related to the maxillary sinus [3].

In this case report, we describe the removal of a dental implant, an impacted third molar and a tooth root with the Caldwell-Luc approach in three different patients with maxillary sinus displacement.

## Case Reports

### Case 1

An eighteen-year-old healthy female patient was referred to our department for the assessment of maxillary right third molar which was accidentally displaced into the maxillary sinus. According to the patient's history, the patient underwent an unsuccessful surgical procedure under local anesthesia performed by a clinician for removal of her impacted right maxillary third molar. The localization of the tooth was detected in the right maxillary sinus with panoramic radiography. (Figure 1A-1B) The cone beam computed tomography (CBCT) taken the next day showed that the tooth was in the apical region of the molar teeth (Figure 1C). The surgical procedure was performed under local anesthesia. The surgical intervention began with the Caldwell-Luc lateral wall approach and the elevation of a trapezoidal full-thickness mucoperiosteal flap was performed. (Figure 1D) The buccal aspect of the flap was raised to access the maxillary sinus bony wall. A low-speed straight hand-piece with a circular diamond bur was used to perform spherical osteotomy. Immediately afterward, the upper third molar was identified and removed with a surgical aspirator and a clamp (Figure 1E). The postoperative healing was uneventful 3 month follow-up period.

### Case 2

A 59-year-old male was referred to our department for the removal of a dental implant that had been displaced to the left maxillary sinus. While the healing cap was being attached, the

implant displaced to sinus because of a successful primary stabilization did not occur. The clinical findings were supported by radiological examination and it was seen that the implant was at the apex of the left upper second molar. (Figure 2A) Because the patient did not have an acute infection, surgical removal of the implant under local anesthesia was decided. The surgical procedure was performed under local anesthesia. The crestal incision and vertical relaxing incisions were made for Caldwell-Luc operation. After removal of the full thickness flap, a rectangular window was removed on the lateral wall of the sinus with a round bur under irrigation of saline solution. (Figure 2B) The granulation tissues inside the sinus were removed with a sinus curette. The implant was removed with surgical aspirator and hemostat (Figure 2C). The postoperative recovery was uneventful 3 month follow-up period.

### Case 3

A forty-five-year-old female patient was referred to us for her maxillary sinus displaced root after tooth extraction. According to the patient's history, it has been learned that the left maxillary sinus area has pain and pressure sensation. Vestibular sulcus has sensitivity in palpation. Oroantral fistula findings were not found. Radiological examination revealed root presence in the left maxillary sinus. (Figure 3) It was determined that there was no acute condition in the patient and it was decided to remove the root with the Caldwell-Luc approach under local anesthesia. The surgical procedure was performed under local anesthesia. The surgical intervention began with the Caldwell-

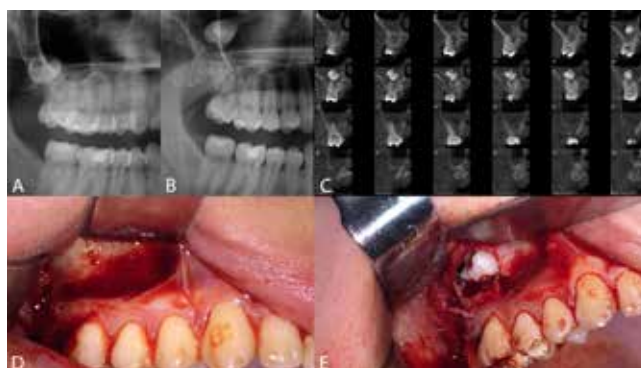


Figure 1. A. Panoramic radiograph before displacement. B. Preoperative radiographs demonstrating migration of tooth in the upper part of the maxillary sinus. C. CBCT image of the displaced tooth. D. Intraoperative view, surgery area. E. The tooth removed from the maxillary sinus during the operation.

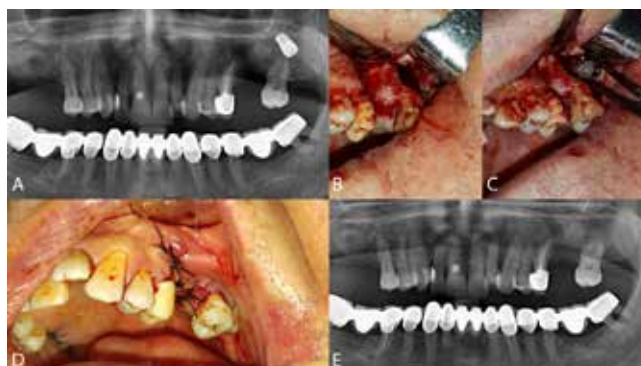


Figure 2. A. Preoperative radiograph. B. Intraoperative view of implant removal through an intraoral approach after having raised a mucoperiosteal flap a small portion of the anterior aspect of the maxillary wall is removed to allow access to the sinus. C. The implant is removed through the intraoral access. D. Suture of the surgical access. E. Postoperative panoramic radiograph.

Luc access bilaterally and the elevation of a trapezoidal full-thickness mucoperiosteal flap. The buccal aspect of the flap was raised to access the maxillary sinus bony wall. The rectangular bone window was removed with the help of piezo-surgery (Figure 4A). The sinus membrane is perforated and the root is reached. (Figure 4B) L-PRF was applied to the surgery area and the removed bone piece was fixed with the aid of a mini screw (Figure 4C-4D). Postoperatively, amoxicillin 1000mg, naproxen 550mg, cetirizine 5mg, pseudoephedrine 125mg, % 0,12 chlorhexidine mouth rinse twice a day were prescribed for a week. The postoperative course was uneventful and the patient was asymptomatic in the three months period of follow-up.

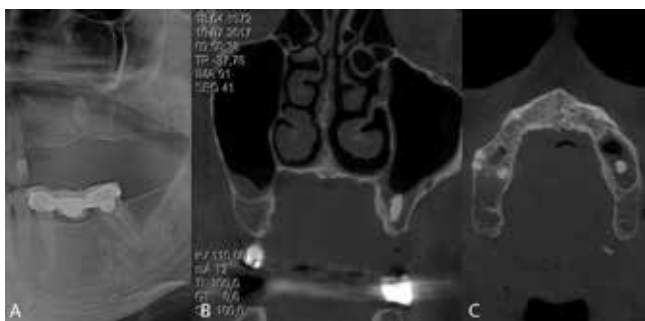

Figure 3. A. Panoramic radiograph showing tooth root displaced into the maxillary sinus. B. CBCT scan demonstrating the displacement of the tooth root into the maxillary sinus, coronal view. C. CBCT scan demonstrating the displacement of the tooth root into the maxillary sinus, axial view.

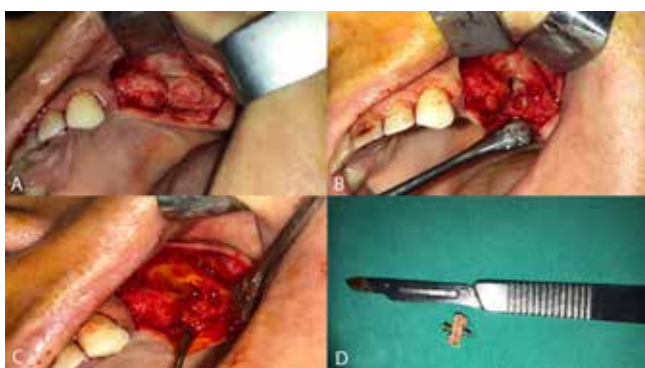

Figure 4. A. The rectangular bone window was removed with the help of piezo-surgery. B. The tooth root is removed through the intraoral access. C. L-PRF was applied to the surgery area. D. The removed bone piece was fixed with the aid of a mini screw.

## Discussion

Because of the anatomical proximity of the upper teeth and dental implant placement in this area, maxillary sinuses are the most important among the paranasal sinuses for clinicians and surgeons in dentistry. Because of this close anatomic relationship, a careful clinical and radiological examination is needed before surgeries made in this area [3]. Maxillary sinus-related complications in dentistry are maxillary sinusitis, oroantral fistula formation and migration of foreign bodies into maxillary sinus [4]. The displacement of foreign bodies into the paranasal sinuses is a rare condition, and migraine usually occurs into the maxillary sinus. However, case reports about migrated implants into ethmoid and sphenoid sinuses are also available in the literature [5]. In such cases, sometimes no symptoms may be observed and this can occur with routine radiographic examinations. Sometimes it causes an infection in maxillary or other paranasal sinuses [6]. The causes of this complication include the

incorrect extraction technique, poor anatomical information, reduced visualization of the surgical field, and complications experienced during sinus lifting operation [7]. In the treatment, there are the following methods as standard Caldwell-Luc operation, transoral functional endoscopic sinus surgery, transnasal functional endoscopic sinus surgery [8].

Surgeries using the standard Caldwell-Luc approach are under local anesthesia. With this method, sinusoid approach is essential by opening a window on the lateral wall of the maxillary sinus. The approach is direct from the opened window and this method is advantageous for the experienced clinician. Comparing the Caldwell-Luc surgery with endoscopic sinus surgery, the main disadvantage of endoscopic sinus surgery is the need for general anesthesia. If the foreign bodies are close to the anterior or inferior wall of the maxillary sinus, it is almost impossible to obtain these objects with a transnasal approach [8]. In this case report, we preferred to receive foreign bodies from the maxillary sinus via Caldwell-Luc operation under local anesthesia.

## Conclusion

As a result, migration of foreign bodies to maxillary sinuses as a result of the surgical procedures performed is an undesirable complication. Careful clinical and radiological examination is necessary to avoid such complications. The Caldwell-Luc lateral wall approach is a simple method for removing maxillary sinus displaced foreign bodies. The biggest advantage is that it is performed under local anesthesia and provides direct visualization.

## Scientific Responsibility Statement

*The authors declare that they are responsible for the article's scientific content including study design, data collection, analysis and interpretation, writing, some of the main line, or all of the preparation and scientific review of the contents and approval of the final version of the article.*

## Animal and human rights statement

*All procedures performed in this study were in accordance with the ethical standards of the institutional and/or national research committee and with the 1964 Helsinki declaration and its later amendments or comparable ethical standards. No animal or human studies were carried out by the authors for this article.*

## Conflict of interest

*None of the authors received any type of financial support that could be considered potential conflict of interest regarding the manuscript or its submission.*

## References

- Costa FS, Bellotti A, Farah GJ, Daniel AN, Camarini ET, Rezende de Moraes Ferreira AC. Surgical management of impacted teeth using three-dimensional computed tomography. *J Craniofac Surg.* 2011; 22(6): 2344-7.
- Tung TC, Chen YR, Santamaria E, Chen CT, Lin CJ, Tsai TR. Dislocation of anatomic structures into the maxillary sinus after craniofacial trauma. *Plast Reconstr Surg.* 1998; 101(7): 1904-8
- Chanavaz M. Maxillary sinus: Anatomy, physiology, surgery and bone grafting related to implantology eleven years of surgical experience (1979-1990). *J Oral Implantol.* 1990; 16: 199-209.
- Jung JH, Choi BH, Zhu SJ, Lee SH, Huh JY, You TM, et al. The effects of exposing

- dental implants to the maxillary sinus cavity on sinus complications. *Oral Surg Oral Med Oral Pathol Oral Radiol Endod.* 2006; 102: 602–5.
5. Haben CM, Balys R, Frenkiel S. Dental implant migration into the ethmoid sinus. *J Otolaryngol.* 2003; 32: 342–44.
6. Galindo-Moreno P, Padial-Molina M, Sánchez-Fernández E, Hernández-Cortés P, Wang HL, O'Valle F. Dental implant migration in grafted maxillary sinus. *Implant Dent.* 2011; 20: 400-5.
7. González-García A, González-García J, Diniz-Freitas M, García- García A, Bullón P. Accidental displacement and migration of endosseous implants into adjacent craniofacial structures: a review and update. *Med Oral Patol Oral Cir Bucal* 2012; 17: 769-74.
8. Felisati G, Lozza P, Chiapasco M, Borloni R. Endoscopic removal of an unusual foreign body in the sphenoid sinus: an oral implant. *Clin Oral Impl Res.* 2007; 18: 776–80.

**How to cite this article:**

Şahin O, Odabaşı O, Aliyev T, Tatar B. Removal of foreign bodies from maxillary sinus: A report of three cases. *Ann Clin Anal Med* 2019;10(4): 513-6.